

OCCURRENCE OF UROLITHIASIS AND ITS SURGICAL MANAGEMENT IN GOATS

B. Ahmmed¹, M. Saha², M. R. Alam^{1*} and M. M. Alam¹

Abstract

The objective of the study was to determine the occurrence and find a suitable surgical method of urolithiasis in goat. To achieve this objective, a retrospective study was conducted to observe the occurrence of urolithiasis in goats at Veterinary Teaching Hospital of Bangladesh Agricultural University in Bangladesh from 2011 to 2020. During this period, 265 cases of urinary obstruction were recorded out of 3237 surgical cases, where 169 cases were in goats. The highest cases of urolithiasis in goat were recorded in the summer season (76 cases 45%), followed by in the winter season (59 cases, 35%) and in the rainy season (34 cases, 20%). Among the affected goats, 42 (25%) patients were between 0 to 3 months old, (88, 52%) patients were between 3 to 8 months old and (39, 23%) patients were over 8 months old. Gender variation was seen where males were mostly affected. Goats castrated at an early age were more affected. From January 2011 to June 2020, 36 goats were treated by the procedure of tube cystostomy. Among them, 28 (78%) goats recovered successfully but 8 (22%) goats did not recover due to farmer's improper management. This study should be helpful for the veterinarian to aware about the occurrence of urolithiasis, and proper surgical management through the tube cystostomy to save economic losses of the goat farmers.

Keywords: Urolithiasis, age, seasons, tube cystostomy, surgical management.

Introduction

The goat population plays an important role in the livestock sector, and a vital role in the economy of Bangladesh. Veterinary practitioners and farmers give due attention to the health of goat, as they are considered one of the major sources of foods of animal origin including milk, meat, and milk products, and high-quality skin (Alam *et al.*, 2005). However, in goats, one of the most important health problems is urine retention and it may occur as a consequence of urolithiasis, which

leads to high economic losses (Ismail, 2018). Urolithiasis can be defined as the formation of urinary calculi (urinary stones), anywhere in the urinary system (Pearle *et al.*, 2007), usually in the kidneys or ureters but may also affect the bladder or urethra. Solid mineral and organic compounds create uroliths and disease occurs by making direct trauma to the urinary tract that obstructs to urinary outflow (Maciel *et al.*, 2017). Calculi formation and urolithiasis development is a complex process which occurs through a series of phases.

¹Department of Surgery and Obstetrics, Bangladesh Agricultural University, Mymensingh 2202, Bangladesh.

²Department of Surgery and Radiology, Faculty of Veterinary Medicine and Animal Science, Bangabandhu Sheikh Mujibur Rahman Agricultural University, Gazipur 1706, Bangladesh. Corresponding author: alammr@bau.edu.bd

Firstly, nidus formation, concentration of urine, and lastly the precipitation of various salts from urine (Makhdoomi and Gazi, 2013). Obstructive urolithiasis is usually associated with the obstruction of the urethra by one or more uroliths, which results in blockage of urine outflow (Radostits *et al.*, 2007; Ewoldt *et al.*, 2008). The obstruction site is usually in areas of the narrowed urethral diameter, more commonly at the urethral process or vermiform appendage of sheep and goats (Van Metre *et al.*, 2004; Ewoldt *et al.*, 2008). Ruminant urolithiasis can be caused by some nutritional diseases and it is considered the primary factor, while sex and hormonal changes are also considered predisposing factors (Kahn *et al.*, 2005). Vitamin A deficiency leads to nidus formation. High-grain diets overwhelm the salivary excretion mechanism and phosphorus is excreted through urinary excretion. (Belknap and Pugh, 2002). When calcium-phosphorus ratios (Ca: P ratios) are not mixed proportionately in food, it causes dietary imbalances and the formation of uroliths and finally crystals in the urine (Makhdoomi and Ghazi, 2013). Excess feeding of Palm kernel cake (PKC), oil palm byproduct causes an imbalance of the calcium-phosphorus ratio, which may lead to the formation of uroliths (Wan Zahari and Alimon, 2012). The optimum level of PKC to be fed to goats is 30%. Castration is an important factor of urolithiasis. Castrated goats are more prone to the formation of uroliths and it is the first cause of death, accounting for 18% to 38% of goat and lamb deaths in winter. When mucoproteins in the urine coalesce, nidus is formed and precipitate with crystals in supersaturated urine (Belknap and Pugh, 2002). If calculi increase in number

or size, up to bladder may result in stones in sheep and bucks (Khan *et al.*, 2013) and it can rapidly progress to the bladder or urethral rupture, uremic crisis. In severe cases, death may occur (Kannan and Lawrence, 2010). Animals affected with obstructive urolithiasis usually show signs of abdominal pain, tail flagging, abdominal swelling (from a ruptured bladder), restlessness, groaning, and grunting while straining to urinate but passing only a few drops of blood-stained urine. Blood clots, crystals, or small stones could be identified on preputial hairs (Belknap and Pugh, 2002; Ewoldt *et al.*, 2008). Swelling around the prepuce can be found in affected animals (Kahn *et al.*, 2005). Sometimes Balanoposthitis, an inflammation of the penis and prepuce can be found in male animals with urethral obstruction (Radostits *et al.*, 2007). In ruminants medical treatment of obstructive urolithiasis is usually unsuccessful. Multiple surgical techniques have been described for the treatment of urolithiasis including urethrostomy (Khan *et al.*, 2009; Azari *et al.*, 2010), urethrotomy (Singh *et al.*, 2010), the penile transaction with urethral fistulation (Misk and Semieka, 2013), laparotomy and urethrotomy (Abdel-Fattah and Sedeek, 2005) and tube cystostomy (Sutradhar *et al.*, 2018). Therefore, the present study aimed to study the occurrence of urolithiasis in goat at Veterinary Teaching Hospital (VTH) in Bangladesh Agricultural University in Bangladesh and to find out the prognosis after surgical management of urolithiasis.

Materials and Methods

Experimental animals

The animals brought to the Veterinary Teaching Hospital (VTH), Bangladesh

Agricultural University (BAU), Mymensingh, Bangladesh and also referred to the Department of Surgery and Obstetrics, Bangladesh Agricultural University (BAU) from 2011 to 2020 for the diagnosis and treatment of urinary obstruction were considered as the experimental animals. Cases were recorded and calculated to determine the occurrence of urolithiasis in goats in that period. The occurrences of urolithiasis in goats were recorded according to age, sex and season. The cases were classified according to Species: Goat; Age: Classification into three, first (0 to 3 months), second (3 to 8 months) and third (Over 8 months); Sex: Male and female were considered; Seasons: Summer season (March–June), Rainy season (July–October), Winter season (November –February) were considered. A thorough clinical examination was done to check the condition of animals and the status of the urethra and urinary bladder. In addition, a rupture in the bladder was also checked by abdominocentesis.

Treatment

The surgical procedure adopted for the treatment of urolithiasis in goats was tube cystostomy.

Anaesthetic protocol

The surgical procedure adopted for the treatment of urolithiasis in goats was tube cystostomy.

Anaesthesia

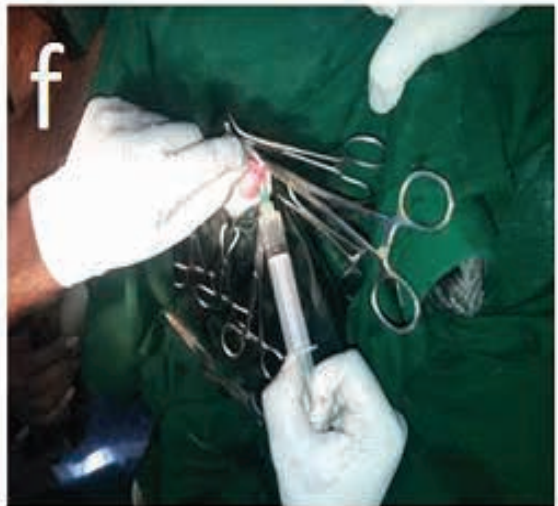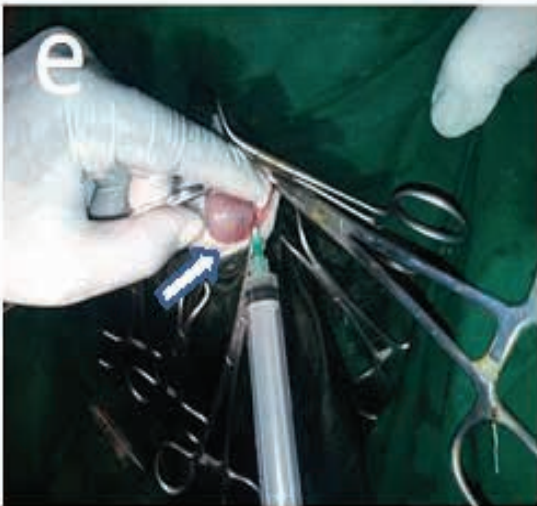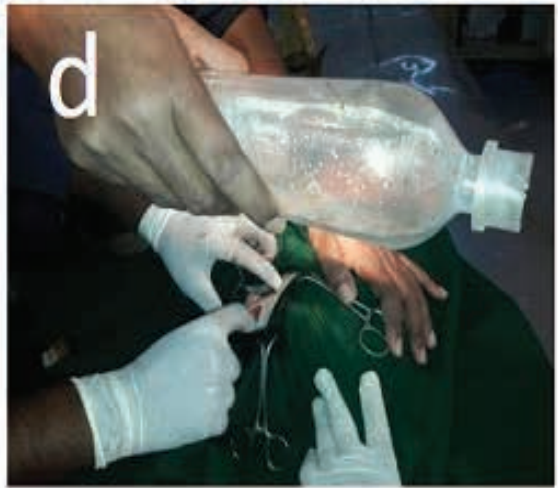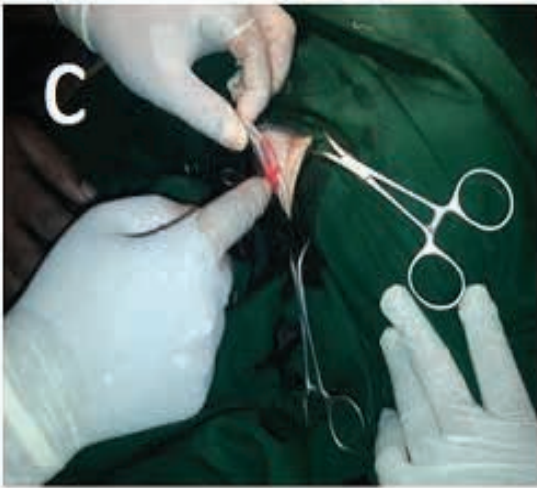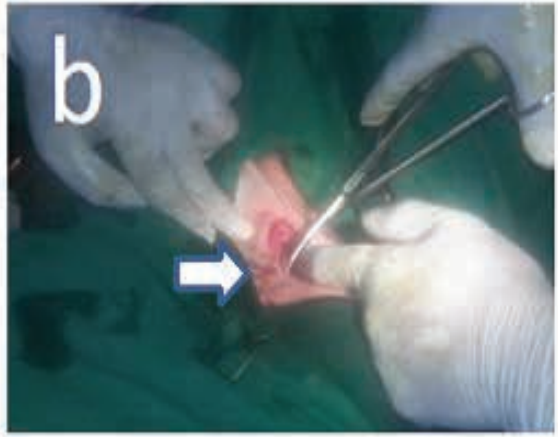
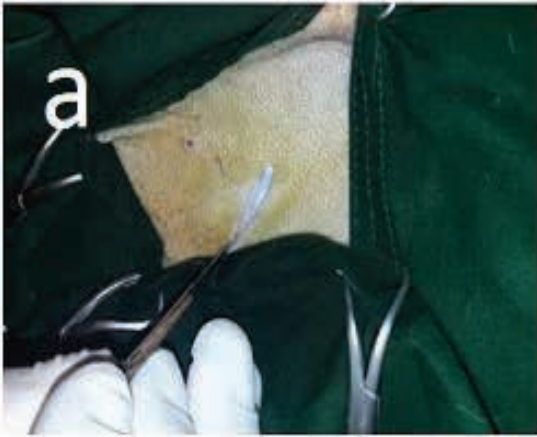
The anaesthetic protocol used was local infiltration and regional anaesthesia. (Lumbosacral epidural) with 2% lignocaine hydrochloride. Dexamethasone (4-8 mg) along with drip (normal saline, 0.5-2.0 Lt depending upon the condition of the animal) was administered in the cases that appeared to be poor surgical risk patients.

Surgical site

Left ventral abdominal area from the level of the umbilicus to the scrotum.

Operative Procedure

The goat was kept in fasting condition for 12 h. Physical examination of the goat as weight, temperature, pulse rate, and respiration rate was done. The goat was controlled in lateral recumbency. The operation site was clipped, washed with soap and water, shaved and painted with povidone-Iodine. Following anaesthesia and aseptic preparation the goat was positioned in right lateral recumbency with the left hindlimb flexed and abducted. Normal Saline was given intravenous route. A 2 cm long paramedian longitudinal skin incision was given 5 cm lateral to the midline and 1-2 cm cranial to rudimentary teats in the prepubic region (Fig. 1a). Bleeding was checked by crushing the cut edges of the skin by artery forceps. The skin was separated from underlying tissues by blunt dissection (Fig. 1b). Dissection of the skin edges at both sides of the ventral fissure was performed. Fascia and rectus abdominis muscles were separated. Foley's catheter was anchored to a K wire by its eye. Urinary bladder was palpated with the index figure of the left (Fig. 1c) hand and a K wire was entered into abdominal cavity so as to reach to the urinary bladder. A syringe and needle were used to drain out of urine (Fig. 1d). After reaching the catheter to the ventral aspect of the bladder, it was pushed with a sudden thrust into the urinary bladder. The balloon of Foley's catheter was immediately inflated with 5-6 ml of sterile saline (Fig. 1e). The K wire was retracted slowly. The external end of the catheter was pulled gently to oppose the bladder wall to the inner aspect of the abdominal wall. Urine started coming



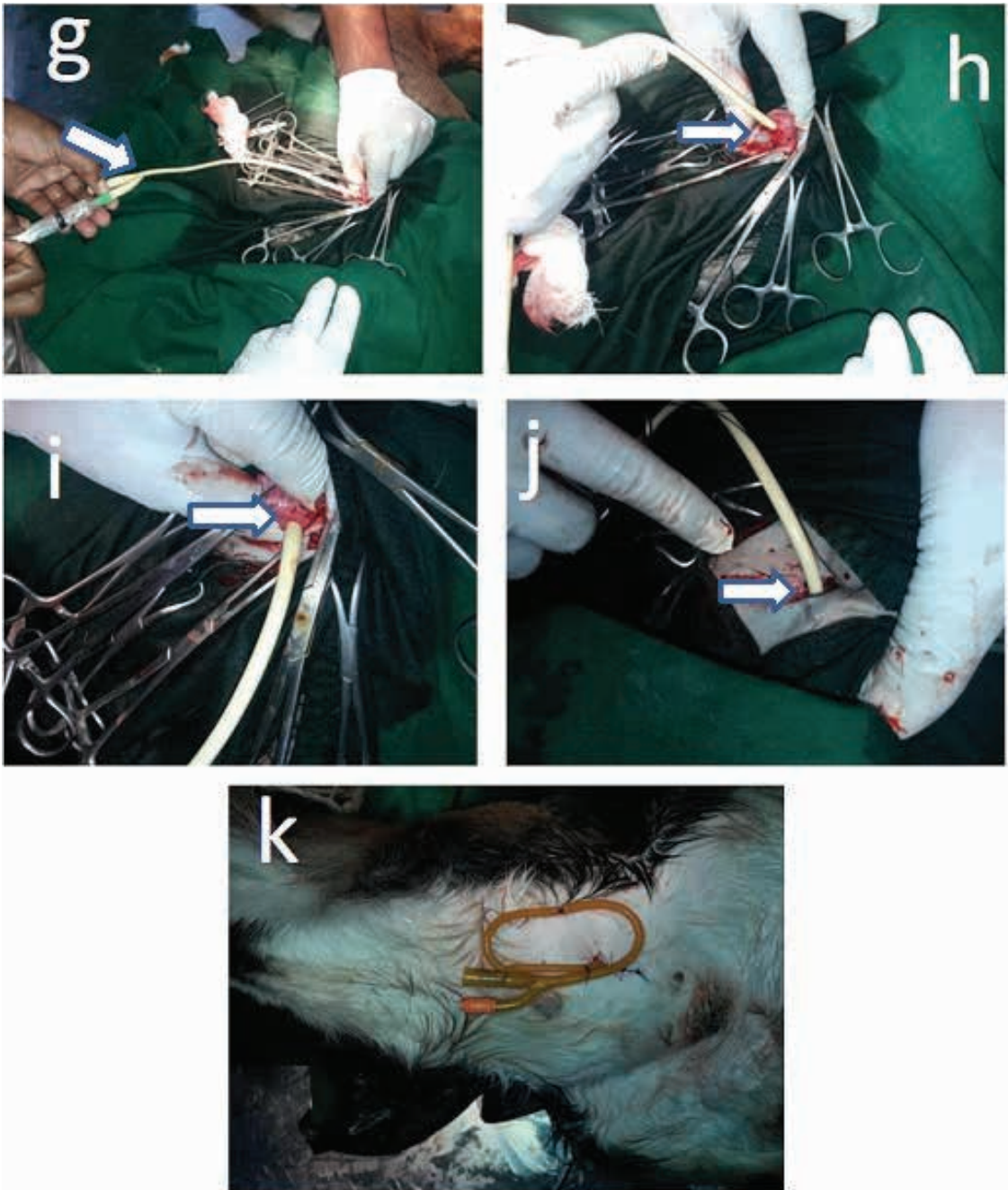


Fig. 1. Surgical procedures of urolithiasis in goat. a) Skin incision b) Incision of muscle layer c) Blunt dissection d) Cleaning and palpation of urinary bladder e) Exteriorization of the urinary bladder and draining of urine f) Inserting catheter in bladder g) Inflated with 5-6 ml of sterile saline h) Fixing of a catheter in muscle layer i) Closing of the bladder by purse string suture j) Muscle layer suturing k) Fixation of the external portion of the catheter.

from the catheter. Additional 10-12 ml of saline was infused into the balloon of the catheter. 20 ml of normal saline was given to wash the abdomen. The abdominal muscle layer was sutured with No.1 Catgut (Fig. 1j). Skin was closed with nylon. Part of Foley's catheter outside the abdomen was fixed with the abdominal wall with 3-4 stitches (Fig. 1k). The suture line was covered by cotton plug soaked with povidone-iodine.

Postoperative Care

Daily dressing of the wound with povidone-iodine solution is continue. Postoperative treatment included (Streptomycin 0.5 gm + Penicillin 4 lac) of Sp- Vet 0.5gm® (ACME Lab, Bangladesh) of 1ml/20 kg body weight intramuscularly twice daily for 7 days after mixing with 1.6 ml distilled water. Non-steroidal anti-inflammatory injection, ketoprofen (injection Kop Vet®, Square pharmaceuticals Ltd., Bangladesh) @ 3 mg/kg body weight intra muscularly daily for 3 days to subside postoperative pain. A low dose of (1 mg/kg body weight) of pheniramine maleate (Histavet®, ACI Animal Health, Bangladesh) once daily was given intramuscularly for 5 days. Plenty of fluid therapy (intravenous route) was administered to the animal to correct the dehydration and uremia. The owner was advised to keep the surgical site clean with antiseptic dressing (twice daily) with the catheter externally for 3 hours daily from day 4 to encourage normal urination. The animals were completely restricted to their stalls and only limited movement was allowed until the healing of the wound. Sutures were removed after 10-12 days on completion of healing. The balloon of the catheter was deflated and

the catheter was removed. The tract left by the catheter was dressed with povidone-iodine solution until healing. The goat was allowed to move freely in an open enclosure after 15 days. During the postoperative period, the goat was closely monitored for the presence of fever, the severity of pain, and secondary bacterial infection.

Results and Discussion

Occurrence of urolithiasis in different years

In this study, 169 cases of goats were affected with urolithiasis where 17 goats in 2011, 21 goats in 2012, 20 goats in 2013, 15 goats in 2014, 17 goats in 2015, 16 goats in 2016, 13 goats in 2017, 18 goats in 2018, 24 goats in 2019, 8 goats in 2020 (Fig. 2).

Occurrence in different seasons

The occurrence of urolithiasis in different seasons from 2011 to 2021 was observed in goats that 76 (45%) affected in the summer season (March to June), 34 (20%) in the Rainy season (July to October) and 59 (35%) in winter (November to February) of the years (Fig. 3). The study revealed that the urolithiasis incidence was the highest during March-June (45%) when temperature and relative humidity were optimum. In the rain and cold seasons, the rate was comparatively low (20% and 35%, respectively). The season had a great effect on the occurrence of urolithiasis. The occurrence of urolithiasis in feedlot animals in winter may be due to the decreased water intake and deficiency of vitamin-A arising from lesser availability of green fodder (Radostitis *et al.*, 2000). Vitamin A is required for the maintenance of epithelial linings and also balances the vitamin D concentration. In

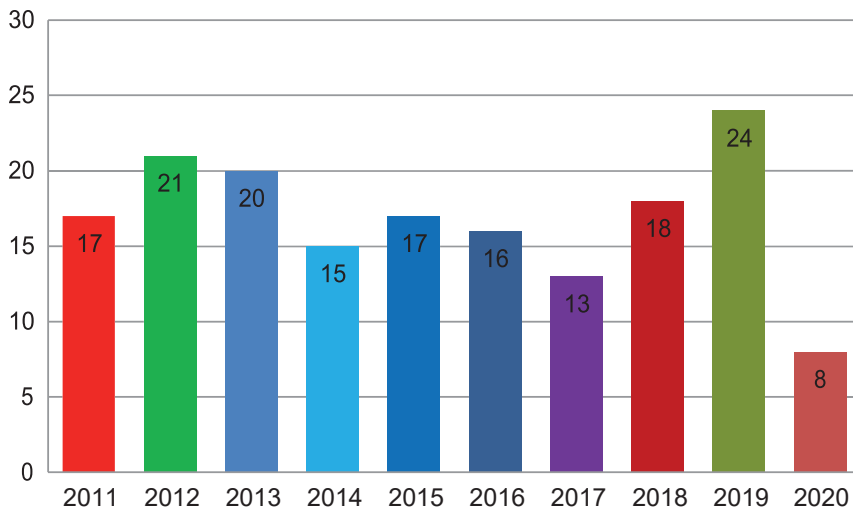


Fig. 2. Occurrence of Urolithiasis in different years.

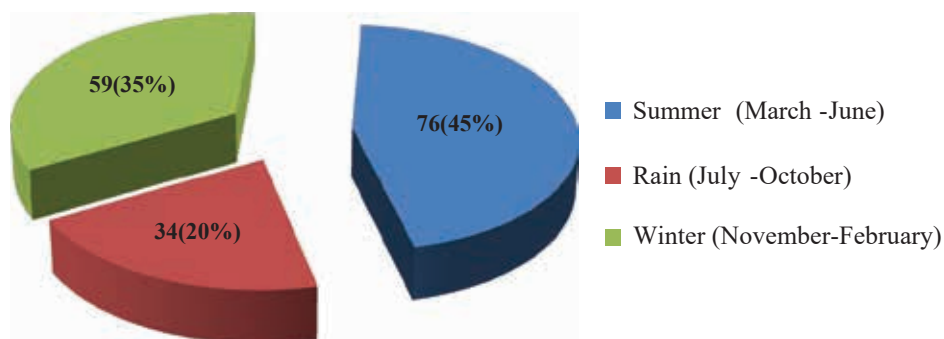


Fig. 3. Effects of season on the occurrence of Urolithiasis.

summer, excess sunlight and vitamin D may play an important role in urolithiasis.

Distribution of urolithiasis based on age of goats

Among the 169 affected goats, the age of 42(25%) patients was 0 to 3 months, 88(52%) goats were 3 to 8 months and 39 (23%) goats were over 8 months (Fig. 4). The contributing factors for more prevalence of obstructive urolithiasis in young ruminants are concentrate diet and changes brought about by weaning in the animal (Radostitis *et al.*, 2000). A large

number of sandy calculi can cause urethral obstruction in young animals which may fill the urethra leading to complete obstruction. Complete urethral obstruction also predisposes younger animals to its rupture (Singh *et al.*, 2008).

Occurrence of urolithiasis in respect to sex in goats

Among 169 recorded cases of goats, male goats were 137 (81%) and female goats were 32(19%). It was clearly understood that male was more prone to urolithiasis than female

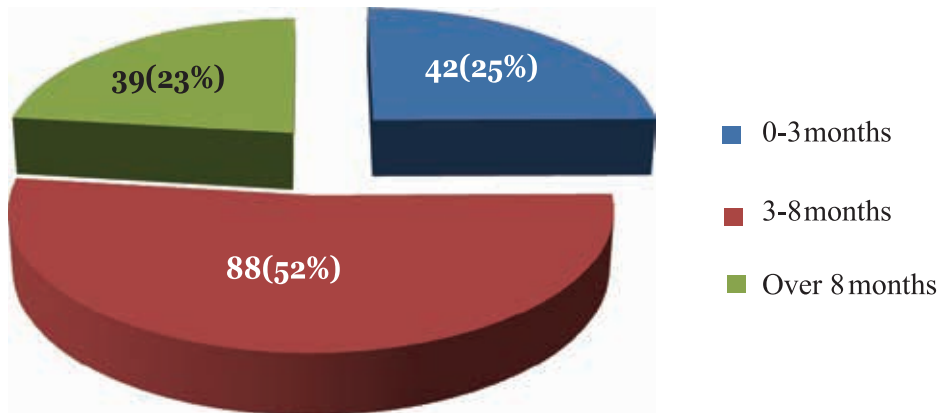


Fig. 4. The occurrence of urolithiasis on the basis of age.

(Fig. 5). Male goats were more affected with urolithiasis after castration. It is believed that castration at an early age could deprive the animal of testosterone required for the normal development of the urethra (Belknap and Pugh, 2002). The absence of testosterone also decreases the protective hydrophilic colloids in the urine, thus increasing the incidence of urolithiasis (Rakestraw *et al.*, 1995). Due to the smaller diameter and more length of

the urethra in males, they are prone to occur urolithiasis (Hesse and Bruhl, 1990; Thilagar *et al.*, 1996).

Urolithiasis in different species

A total number of 265 animals of different species were brought to Veterinary Teaching Hospital (VTH) with urinary incontinence. Out of 265 cases, urolithiasis-affected animals, 169 (64%) were recorded in goats, 95 (36%)

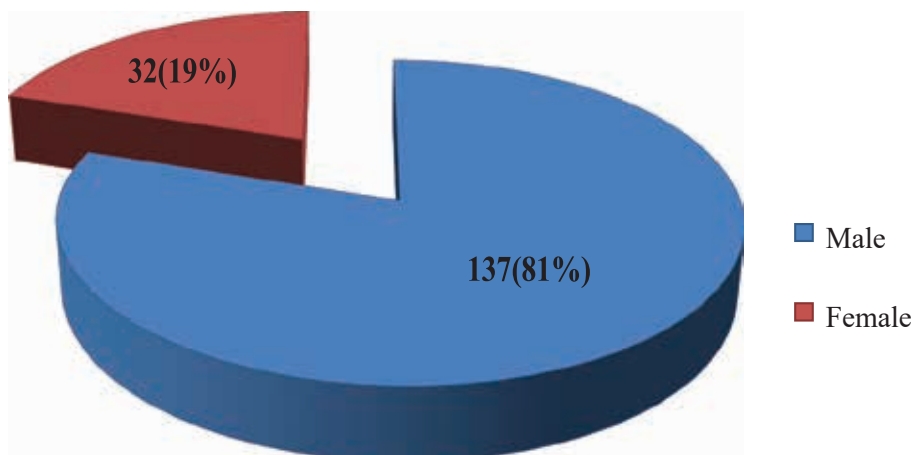


Fig. 5. The occurrence of urolithiasis on the basis of sex.

in cattle, and 1(0.38%) in buffalo (Fig. 6). The exact cause of more incidences of calculi in goats is difficult to pin point based on this study. Calculi formation in the urinary tract of the animals occurs as a result of interaction of various physiological, nutritional and managerial factors (Gutierrez *et al.*, 2000). Calculi are more common in animals which are managed on rations composed of mainly grains (Radostits *et al.*, 2000). Wheat bran is a high concentrate ration, which could be the cause of calculi formation in large number of goats. Wang *et al.* (1997) also reported more incidence of urolithiasis in animals fed high grain diet with calcium: phosphorous ratio as low as 1:1. Green fodder production and availability is less in our urban conditions and the animals were maintained on high grain diet. Additional quantity of concentrate ration can compensate the deficiency of green fodder, which could have precipitated in urolithiasis.

Prognosis of urolithiasis in goats by tube cystostomy

In 10 years, 36 goats were treated by the procedure of tube cystostomy (Fig. 1). Among them, 28 (78%) goats were

recovered successfully but 8 (22%) goats were not recovered due to poor postoperative management. Therefore, the present study was planned with the objectives to evaluate the recovery rate after surgical urolithiasis cases. Surgery is considered the primary treatment of obstructive urolithiasis (Larson, 1996; Van Metre *et al.*, 1996). Surgical correction is the only way to restore normal function in the urinary system. The purpose of the operation was to make the animal urinate. We performed cystostomy with easily available and cheap infusion set tubing. In 2010, Fazili *et al.* also reported the use of an infusion set for tube cystostomy for the treatment of urolithiasis in goats. Urinary catheterization is used in the animal emergency setting. It is used for diagnostic, treatment, and monitoring purposes of the animal. For recovery of diseases appropriate surgical approach, proper placement of the catheter and post-operative care are the most important factors. Tube cystostomy with infusion set tubing was found to be a useful, easy, quick, cheap, and field-applicable technique. Surgical tube cystostomy is the most significant procedure

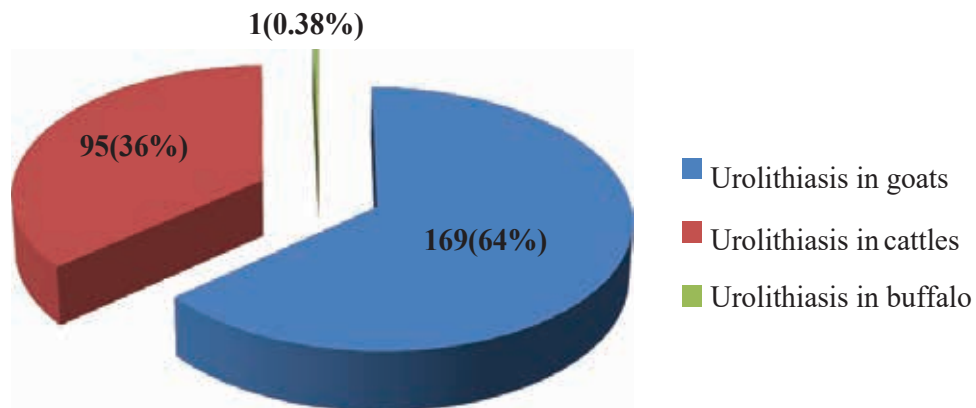


Fig. 6. The occurrence of urolithiasis on the basis of species.

for urolithiasis in goats as well as other animals. The procedure is relatively simple, requiring a short duration of anesthesia and it results in the restoration of full urethral patency in successful cases (Fortier *et al.*, 2004; Ewoldt *et al.*, 2008). Moreover, the incision site healed properly and the cutaneous sutures were removed on the day of catheter withdrawal. The urinary bladder has a high regenerative capacity and heals readily (Rasmussen, 1967). Goats presented with a history of no urination and clinical signs suggestive of urolithiasis were subjected to detailed physical and close examination and ultrasonography was done for accurate confirmation of urolithiasis. Sonography is a non-invasive reproducible and inexpensive method for diagnosis of urolithiasis, localization of urethral calculi and rupture of the urethra or the urinary bladder (Braun, 1993). As it does not involve the use of ionizing radiation, it is safer for both patient and the operator. Tube cystostomy is not free from complications and some complications involved are leakage, wound infection, or dehiscence problems with the tube itself such as irritation at the stoma site, obstruction or accidental dislodgment, and problems related to ascending infection due to the presence of the tube (Bhokre *et al.*, 2010). In our study, there was no major complication such as significant wound infection, complete dehiscence of suture, and no obstruction in the artificial opening. Nylon sutures were removed 10- 12 days after the operation. The kind of suture materials had no significant effects on the occurrence of postoperative complications. Before definitive repair of the urethra or urinary tract, shock, anuria, dysuria,

uremia, dehydration, electrolyte imbalances, and anorexia must be recognized and corrected. It helps the veterinary surgeon to adopt the cheapest method like tube cystostomy to correct urolithiasis. In developing countries like Bangladesh, this technique is particularly advantageous as it is cheap. The knowledge derived from this study will increase the clinicians understanding of the influence of factors like age, sex, castration, season, genotype, and malnutrition. This study will help to take necessary preventive measures for the disorders

Conclusion

The urolithiasis was most prevalent at the age of 3 to 8 months in goats. The occurrence of urolithiasis was comparatively higher in goats than in any other species. The occurrence of urolithiasis in goat was comparatively high in the summer seasons (March- June) and winter seasons (October-March) than in any other seasons. The male goats were more prone to urolithiasis than female goats. Tube cystostomy was found as an effective tool for the surgical management of urolithiasis in goat, where the conservative medical treatment regimens failed. It is suggested to the farmers that castration at the early stage should be stopped, and sufficient water should provide to the goats, and dry and hygienic conditions should be maintained for keeping the goat.

Acknowledgements

The authors are highly thankful to the Director and staff of the Veterinary Teaching Hospital of Bangladesh Agricultural University for providing the necessary facilities.

References

- Abdel-Fattah, M. and A. M. Sedeek. 2005. Dorsal versus ventral urethrotomy technique for treatment of obstructive urethrolithiasis in cattle calves. *Assiut. Vet. Med. J.* 51: 198-209.
- Alam, M. M., S. A. Islam, Y. Mohammed, N. S. Juyena and M. A. Hashim. 2005. Comparative efficacy of two medicinal plant extracts and an antibiotic on wound healing. *Pakistan J. Biol. Sci.* 8: 740-743.
- Azari, O., E. Sakhaee and L. Emadi. 2010. Permanent urethrostomy for treatment of caprine hypospadias. *Am. J. Anim. Vet.* 5: 107-110.
- Belknap, E. B. and D. G. Pugh. 2002. Diseases of the urinary system: In Sheep and Goat Medicine. Edited by Pugh, D. G., and W. B. St. Louis, MO: W. B. Saunders Company, Pp. 255-276.
- Bhokre, A. P., G. Negash, B. Gebrekidan, G. Gugsu and G. Tadesse. 2010. Surgical management of urethral obstruction in three bullocks. *Ethiop. Vet. J.* 14: 137-147.
- Braun, U. 1993. Ultrasonographic examination of the left kidney, the urinary bladder, and the urethra in cows. *J. Vet. Med.* 40: 1-9.
- Ewoldt, J. M., M. L. Jones and M. D. Miesner. 2008. Surgery of obstructive urolithiasis in ruminants. *Vet. Clin. North Am. Food Anim. Pract.* 24: 455-465.
- Fazili, M. R., H. U. Malik and H. K. Bhattacharyya. 2012. Minimally invasive surgical tubecystotomy for treating obstructive urolithiasis in small ruminants with an intact urinary bladder. *Vet. Res.* 166: 528-531.
- Fortier, L. A., A. J. Gregg, H. N. Erb and S. L. Fubini. 2004. Caprine obstructive urolithiasis: requirement for 2nd surgical intervention and mortality after percutaneous tube cystostomy, surgical tube cystostomy, or urinary bladder marsupialization. *Vet. Surg.* 33: 661-667.
- Gutierrez, C., E. Escolar, M. C. Juste, M. P. Palacios and J. A. Corbera. 2000. Severe urolithiasis due to trimagnesium orthophosphate calculi in a goat. *Vet. Rec.* 146: 534.
- Hesse, A. and M. Bruhl. 1990. Urolithiasis in dogs, epidemiological data and analysis of urinary calculi. *Kleintierpraxis.* 35: 505-512.
- Ismail, H. T. H. 2018. Hemato-biochemical parameters as comparative tools and prognostic indicators in urine retention cases with an intact or ruptured urinary bladder in buffalo calves. *Adv. Anim. Vet. Sci.* 6: 148-155.
- Kahn, C. M., S. Line and S. E. Aiello. 2005. The Merck Veterinary Manual, 9th ed. Whitehouse Station, N. J., USA, Pp. 1249-1287.
- Kannan and Lawrence. 2010. Urethra recess in male goats, sheep, cattle and swine. *J. Am. Vet. Med. Assoc.* 191: 689-691.
- Khan, S. A., M. M. Hassan, M. F. Hossain and J. H. Epstein. 2009. Correction of urolithiasis in male calf by ischial urethrotomy. *Intas. Polivet.* 10: 255-257.
- Larson, B. L. 1996. Identifying, treating, and preventing bovine urolithiasis. *Vet. Med.* 91: 366-377.
- Maciel, T. A., I. A. Ramos, R. J. da Silva, P. C. Soares, C. C. D. Carvalho, R. J. D. S. M Júnior, L. Amoroso, S. M. B. Artoni, J. A. B. Afonso, D. Oliveira. 2017. Clinical and Biochemical Profile of Obstructive Urolithiasis in Sheep. *Acta Sci. Vet.* 45: 1-15.
- Makhdoomi, D. M. and M. A. Gazi. 2013. Obstructive urolithiasis in the ruminants-A review. *Vet. World.* 6: 233-238.
- Misk, N. A., T. N. Misk and M. A. Semieka. 2013. Diagnosis and treatment of affections of the urethra in male ruminants: A review of 403 cases. *Int. J. Vet. Reg.* 13: 1-10.

- Radostits, O. M., D. C. Blood, C. C. Gay and K. W. Hinchcliff. 2000. *Veterinary Medicine: a textbook of the diseases of cattle, sheep, pigs, goats and horses*. Edition 9th WB Saunder, Pp. 493-498.
- Radostits, O. M., C. C. Gay, K. W. Hinchcliff and P. D. Constable. 2007. *Veterinary Medicine*. 10th ed, London, 573 P.
- Rakestraw, P. C., S. L. Fubini, R. O. Gilbert and J. O. Ward. 1995. Tube cystotomy for treatment of obstructive urolithiasis in small ruminants. *Vet. Surg.* 24: 498-505.
- Rasmussen, F. 1967. Biochemical analysis of wound healing in the urinary bladder. *Surg. Gynecol. Obstet.* 124: 553-561.
- Singh, B. P., M. G. Andankar, S. K. Swain, K. Das, V. Dassi, H. K. Kaswan and H. R. Pathak. 2010. Impact of prior urethral manipulation on outcome of anastomotic urethroplasty for post-traumatic urethral stricture. *Urology.* 75: 179-182.
- Sutradhar, B. C., T. Dey, S. K. Yadav and M. B. Bostami. 2018. Surgical Management of Obstructive Urolithiasis in Small Ruminants by Tube Cystostomy in Chittagong, Bangladesh. *J. Agric. Sci.* 8: 89-98.
- Thilagar, S., N. N. Balasubramanian, D. Archibald. 1996. A retrospective study of urinary obstruction in dogs-a radiographic study. *Indian Vet. J.* 73: 1183- 84.
- Pearle, M. S. and M. I. Resnick. 2007. (ed.) *Urolithiasis*. Saunders.
- Van Metre, D. C., J. K. House, B. P. Smith, L. W. George, S. M. Angelos, J. A. Angelos and G. Fecteau. 1996. Obstructive urolithiasis in ruminants: medical treatment and urethral surgery. *Compend. Contin. Educ. Vet.* 18(3): 317-327.
- Khan, M. A., D. M. Makhdoomi, A. G. Mohsin and G. N. Shiekh. 2013. Clinico-sonographic evaluation based surgical management of urolithiasis in young calves. *Afr. J. Agric.* 8(48): 6250-6258.
- Mohamed, W. Z. and A. R. Alimon. 2012. Recent advances in the utilization of oil palm by-products as animal feed. *Int. Conf. Live. Prod. Vet. Tech.* 1(4): 211-219.
- Wang, X., K. Huang, J. Gao, X. Shen, C. Lin and G. Zhang 1997. Chemical composition and microstructure of uroliths and urinary sediment crystals associated with the feeding of high level cottonseed meal diet to water buffalo calves. *Res. Vet. Sci.* 62: 275 - 280.